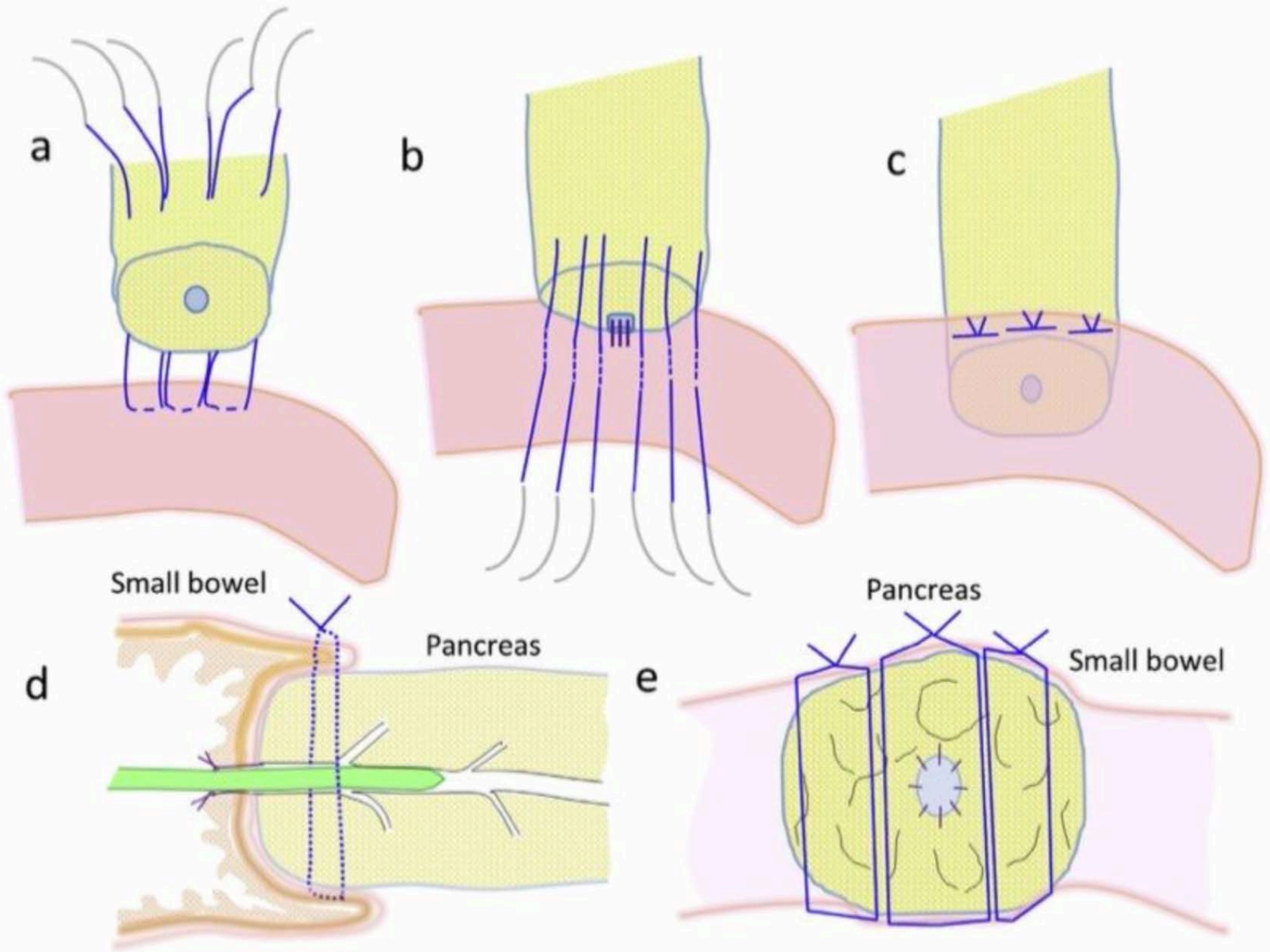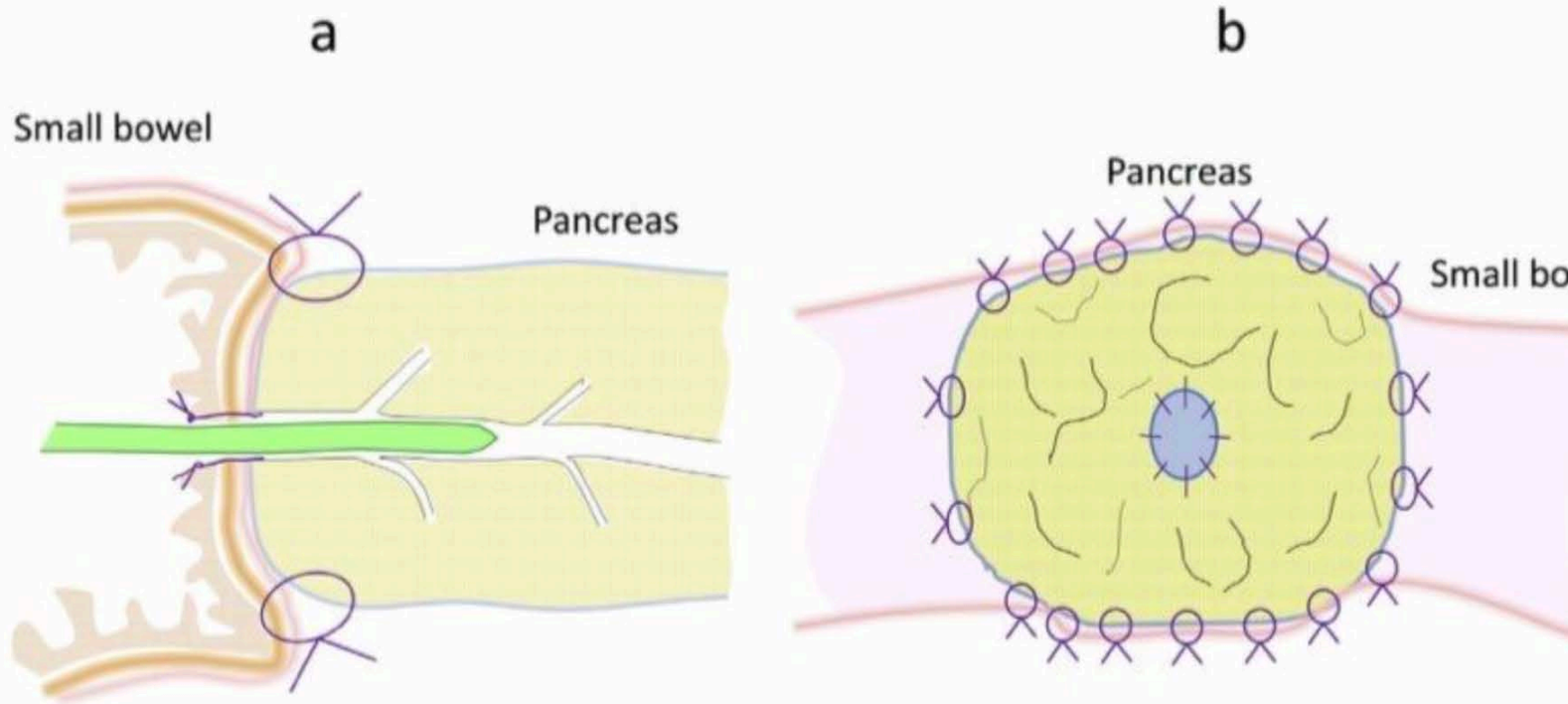


Blumgart anastomosis

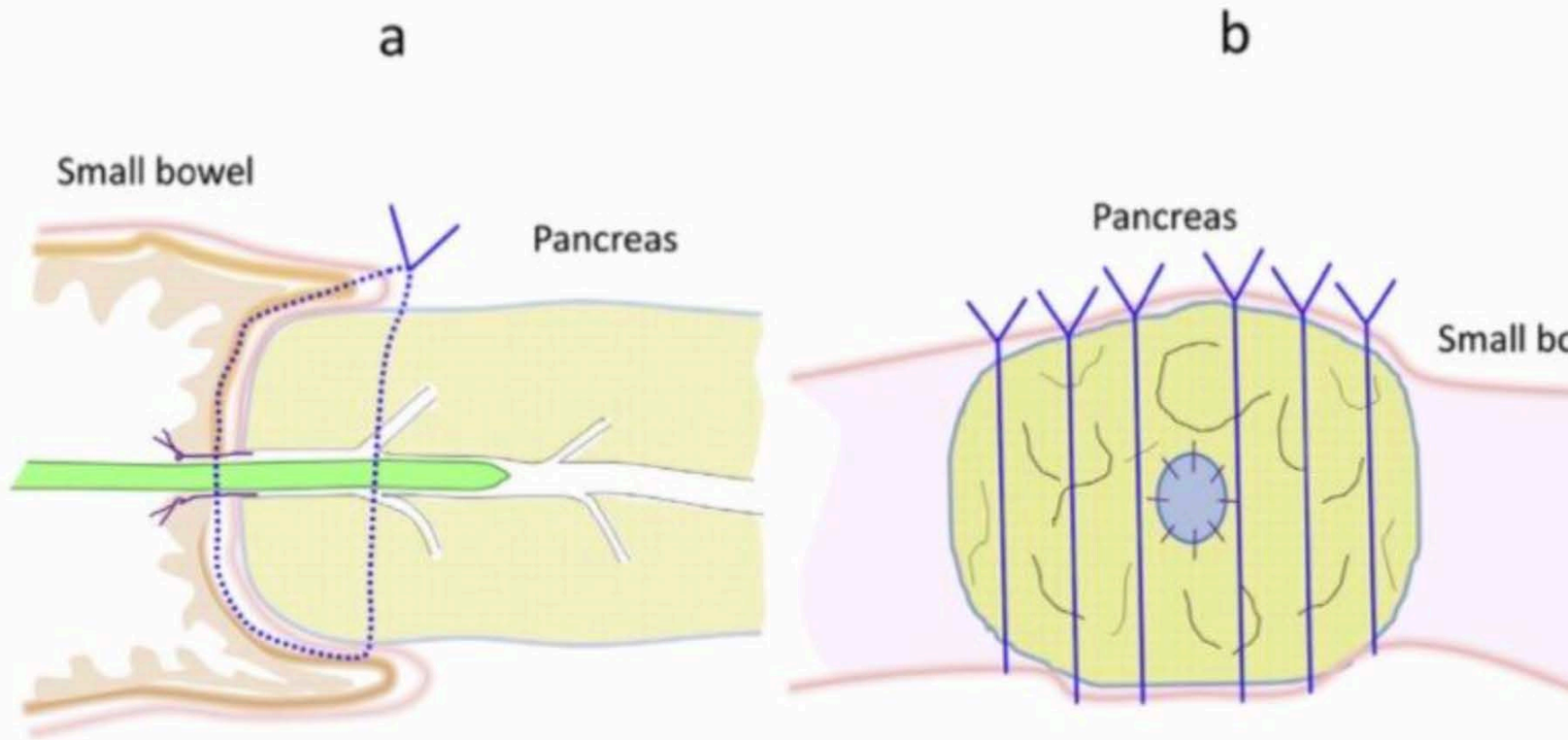


**Figure 1.** Scheme of Cattell-Warren anastomosis.

a. Longitudinal view.

b. Transverse view.

Many sutures are placed tangentially through the pancreatic stump. These might cause lacerations of pancreatic parenchyma.



**Figure 2.** Scheme of modified Kakita anastomosis.

a. Longitudinal view.

b. Transverse view.

Six sutures are placed tangentially through the pancreatic stump, as in the Cattell-Warren anastomosis. These sutures also cut the pancreatic parenchyma.