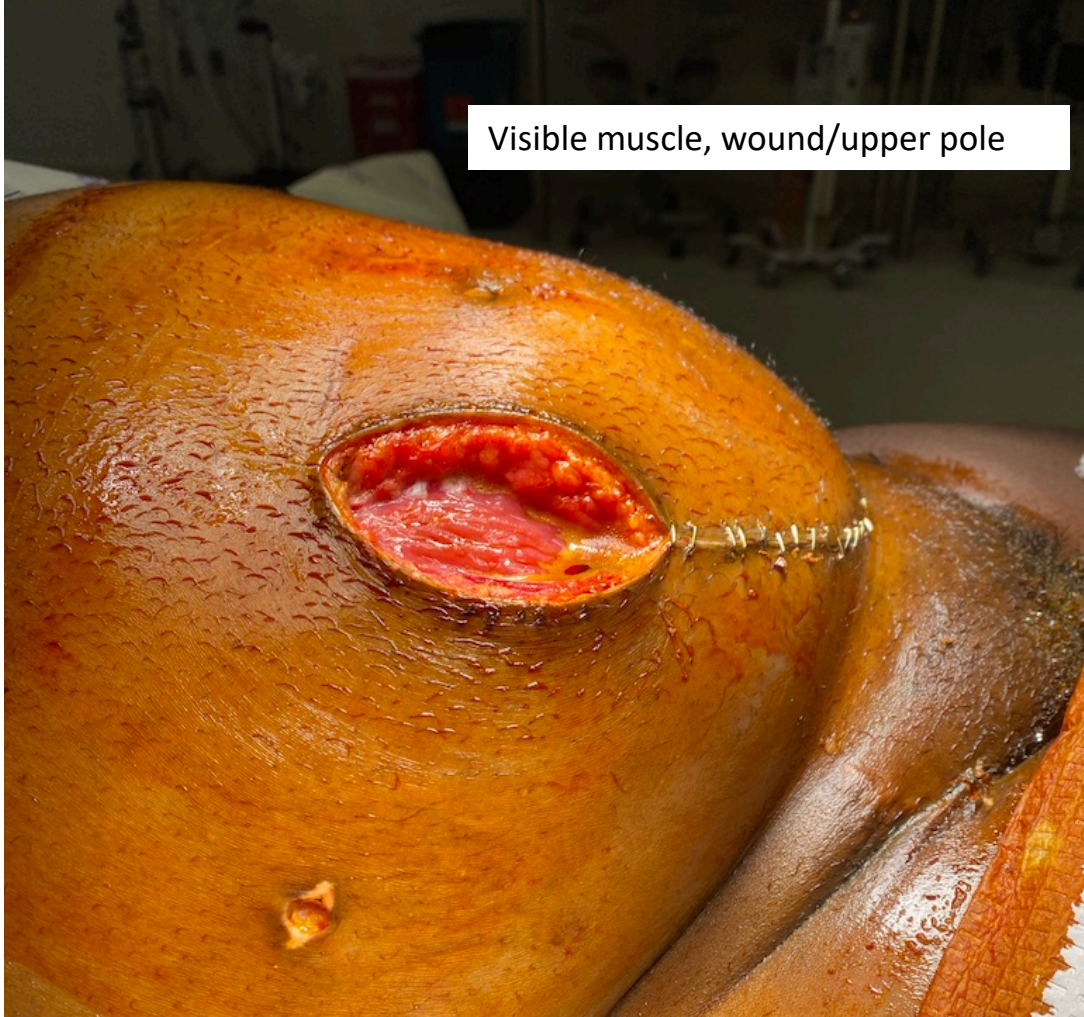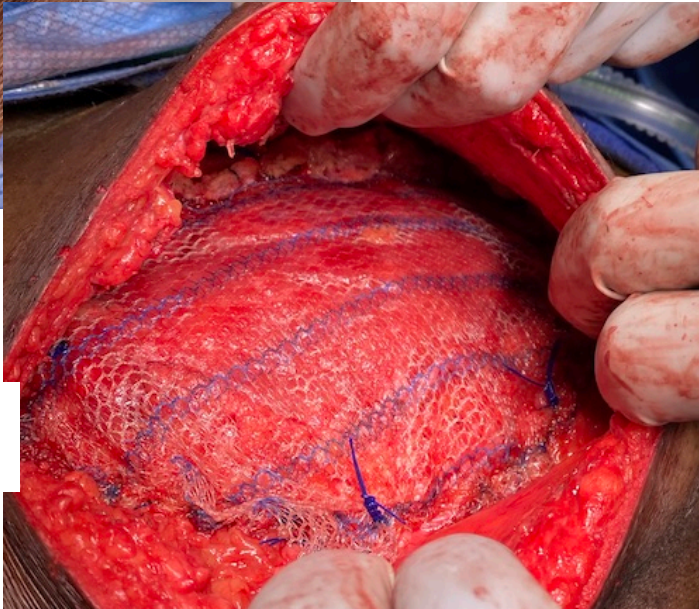

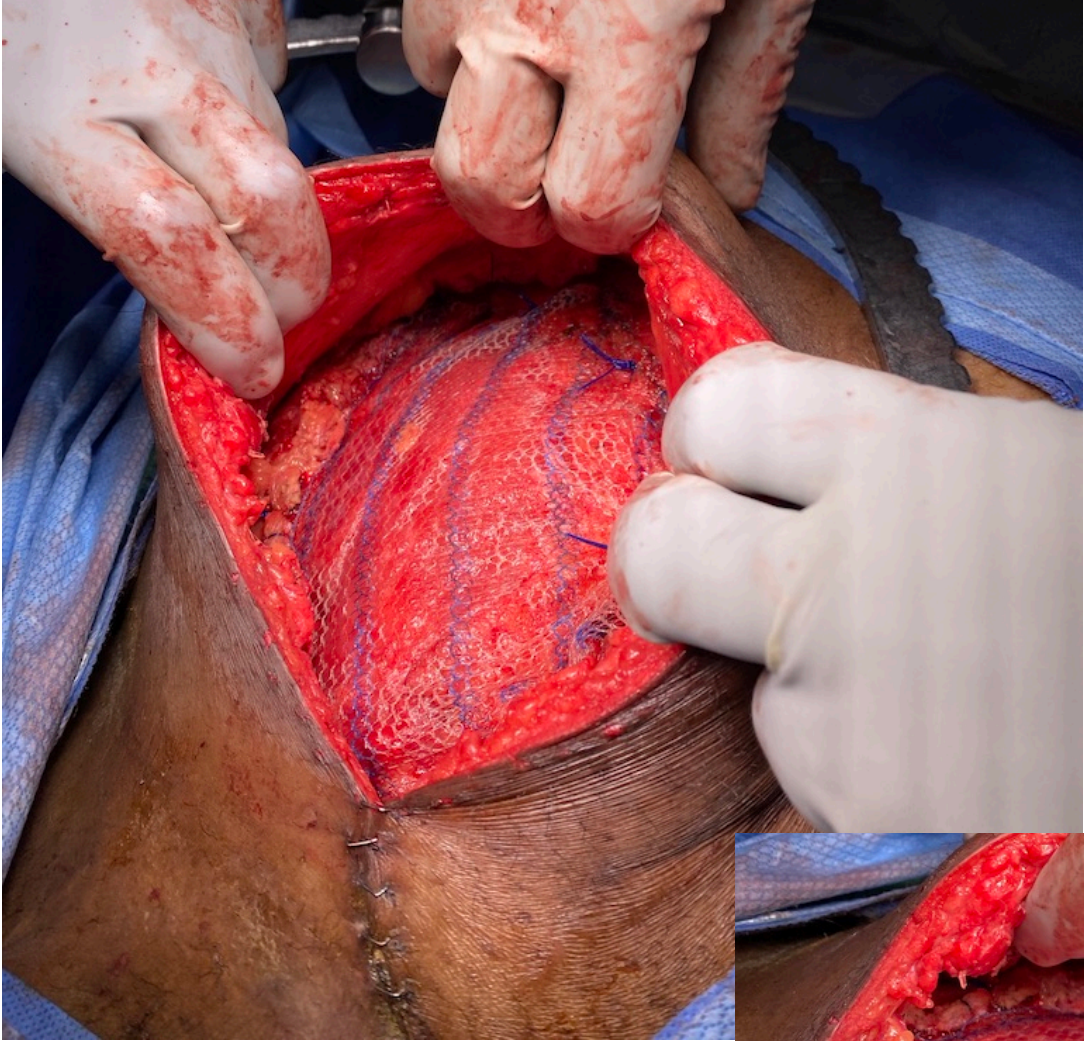
Aug 2020- HTx+ KTx, POD 7 Ogilvie syndrome, POD 3 weeks- seroma,



Visible muscle, wound/upper pole



Bridging the fascial defect with PP mesh sutured around to fascia over the muscle,