

Pancreatectomy and Simultaneous Islet Autotransplantation (Plates XXIII–XXIV)

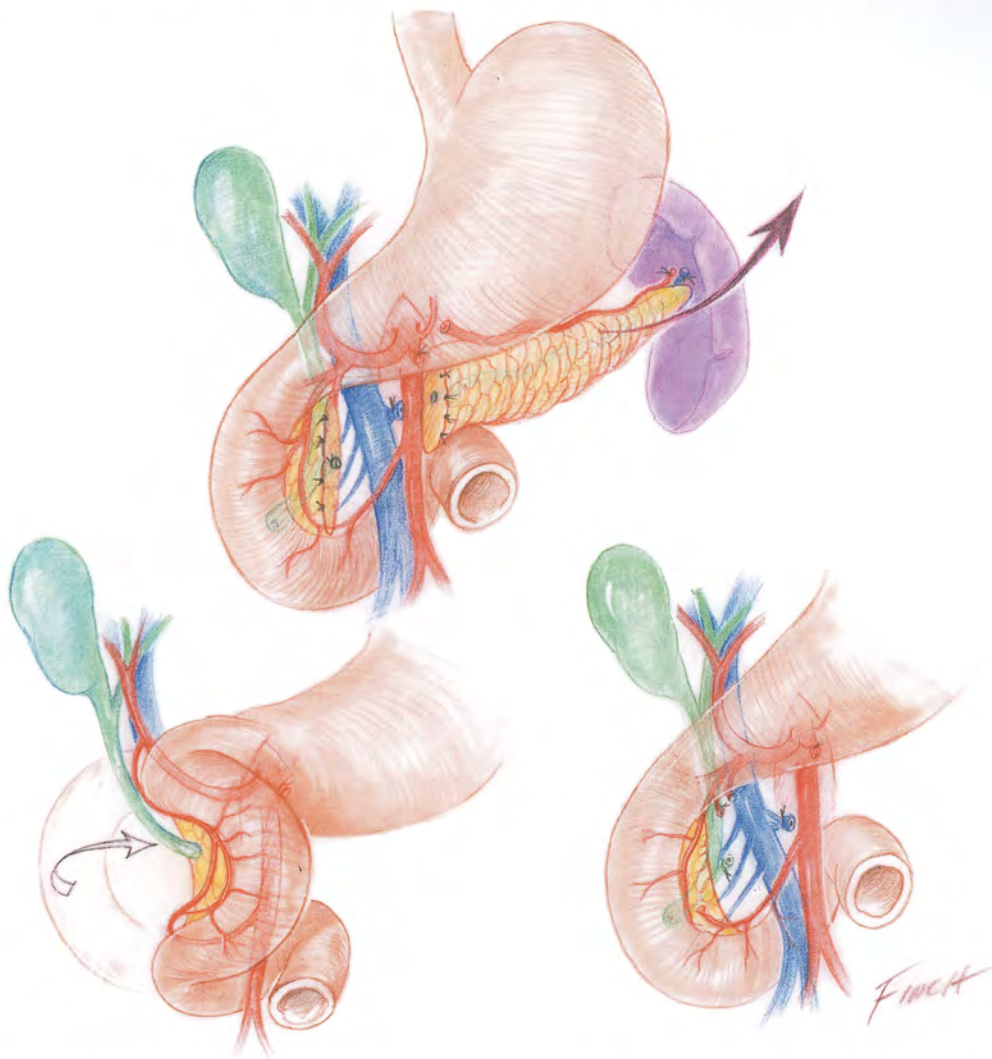


FIGURE 22.1. Near-total pancreatectomy. A small pancreatic rim remains. The superior and inferior pancreaticoduodenal arcades are (whenever possible) preserved for arterial blood supply to the pan-

creatic rim, duodenal loop, and distal common bile duct. The spleen is (whenever possible) preserved.

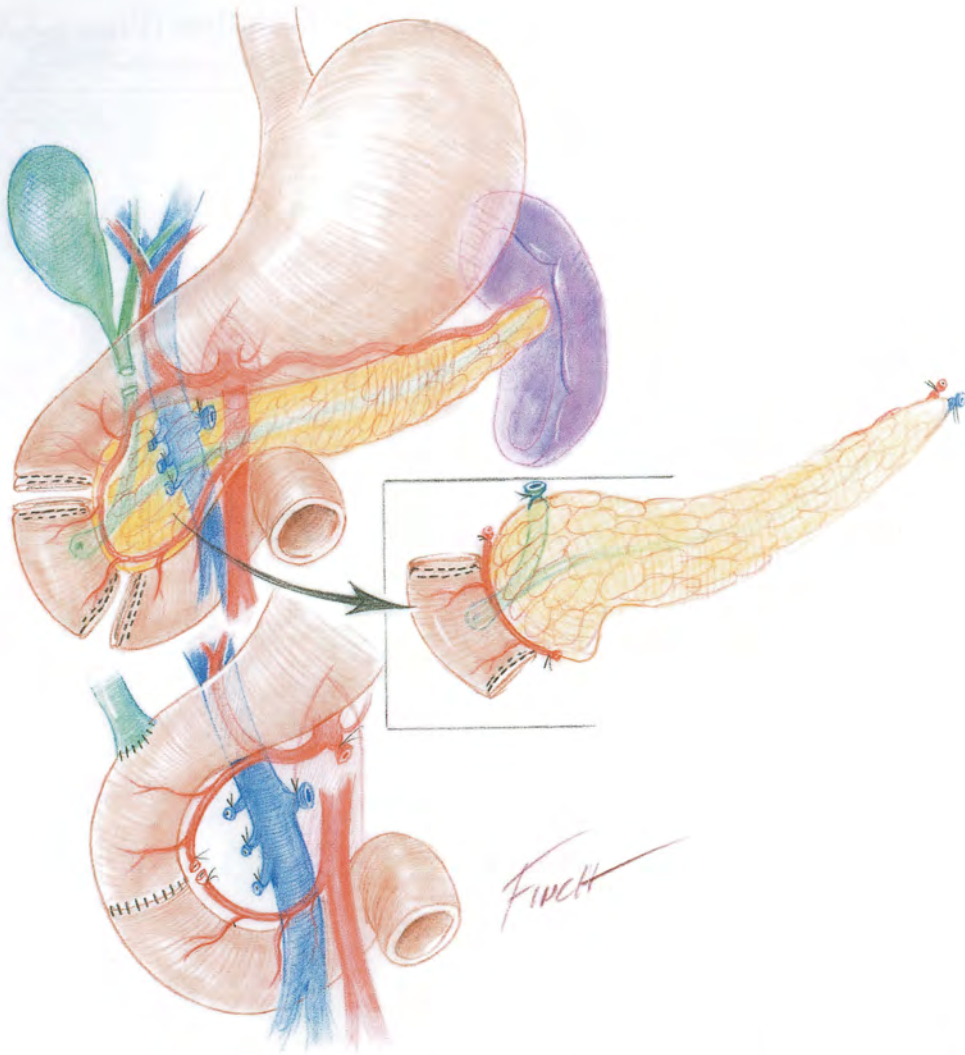


FIGURE 22.2. Total pancreatectomy (with preservation of the pylorus). The bile duct is transected and reimplanted into the duodenum. The second portion of the duodenum is resected and an end-

to-end duodenoduodenostomy is created. The superior and inferior pancreaticoduodenal arcades as well as the spleen are (whenever possible) preserved.